

Short Versus Long Cephalomedullary Nails for Pertrochanteric Hip Fracture

NICHOLAS B. FRISCH, MD, MBA; NICKOLAS J. NAHM, MD; JAD G. KHALIL, MD; CLIFFORD M. LES, DVM, PHD; STUART T. GUTHRIE, MD; MICHAEL A. CHARTERS, MD, MS

abstract

This study compared patients who underwent treatment with short or long cephalomedullary nails with integrated cephalocervical screws and linear compression. Patients with AO/OTA 31-A2 or A3 pertrochanteric fractures treated with either short (n=72) or long (n=97) InterTAN (Smith & Nephew, Memphis, Tennessee) cephalomedullary nails were reviewed. Information on perioperative measures (estimated blood loss, surgical time, and fluoroscopy time) and postoperative orthopedic complications (infection, implant failure, screw cutout, and periprosthetic femur fracture) was included. Estimated blood loss (short nail, 161 mL; long nail, 208 mL; $P=.002$) and surgical time (short nail, 64 minutes; long nail, 83 minutes; $P=.001$) were lower in the short nail group. There were no differences in fluoroscopy time (short nail, 90 seconds; long nail, 142 seconds; $P=.071$) or rates of infection (short nail, 1.4%; long nail, 3.1%; $P=.637$) or overall orthopedic complications (short nail, 11.1%; long nail, 9.3%; $P=.798$) between the 2 groups. The long nail group had a trend toward more screw cutouts (long nail, 5.2%; short nail, 0.0%; $P=.134$) but fewer periprosthetic femur fractures (short nail, 8.3%; long nail, 0.0%; $P=.013$). This study found a similar overall rate of orthopedic complications between short and long nails with integrated cephalocervical screws and linear compression. These results confirm the suspected advantages of short nails, including faster surgery and less blood loss; however, the rate of periprosthetic femur fracture remains high, despite changes to implant design. [*Orthopedics*. 201x; xx(x):xx-xx.]

may act as a lateral buttress to prevent lateral migration of the proximal fragment. Another theoretical biomechanical advantage of an intramedullary device is that the nail is closer to the axis of weight bearing and could result in greater transmission of physiologic load through the medial calcar. However, a biomechanical study by Rosenblum et al³ showed that the Gamma nail (Stryker, Kalamazoo, Michigan) was stiffer than a sliding hip screw device, leading to less load transmission through the medial calcar and greater compressive load at the tip of the nail. They suggested this as an explanation for the high rate of fractures at the tip of the first-generation Gamma nail.³

The authors are from the Department of Orthopaedic Surgery (NBF, NJN, STG, MAC), Henry Ford Hospital, Detroit; the Department of Orthopaedic Surgery (JGK), William Beaumont Hospital, Royal Oak; and the Department of Pathobiology and Diagnostic Investigation (CML), College of Veterinary Medicine, Michigan State University, East Lansing, Michigan.

The authors have no relevant financial relationships to disclose.

Correspondence should be addressed to: Michael A. Charters, MD, MS, Department of Orthopaedic Surgery, Henry Ford Hospital, 2799 W Grand Blvd, CFP-6, Detroit, MI 48202 (mcharte1@hfhs.org).

Received: February 8, 2016; Accepted: September 29, 2016.

doi: 10.3928/01477447-20161116-01

Despite evidence suggesting a decline in the incidence of hip fracture in the United States, perhaps related to improved multidisciplinary management of osteoporosis, there is concern that the aging population will lead to

an increase in the incidence of hip fracture worldwide.¹ In treating these fractures, an intramedullary device has a biomechanical advantage over a plate-screw device. A biomechanical study by Kubiak et al² suggested that an intramedullary device

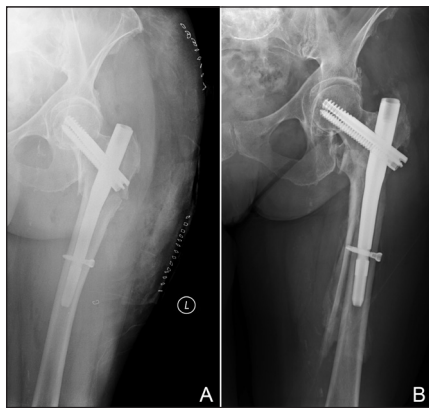


Figure: Anteroposterior radiograph showing a short cephalomedullary nail in a 75-year-old woman after pertrochanteric femur fracture (A). Anteroposterior radiograph showing periprosthetic fracture 32 days after the index procedure (B). The patient underwent revision to a long cephalomedullary nail.

In clinical studies, the first generation of the Gamma nail was associated with a periprosthetic fracture rate of 2% to 11%.⁴ In 3 studies, newer generations of the Gamma intramedullary nail were associated with periprosthetic fracture rates of 0% to 2.2%, similar to the rates with sliding hip screws.⁵⁻⁷ The device used at the study sites, the InterTAN cephalomedullary nail (Smith & Nephew, Memphis, Tennessee), has an integrated cephalocervical and linear compression screw, a feature not found in other devices that are more extensively studied.⁸ In the few studies examining this device, the rate of periprosthetic fracture was 0% to 8%, but the number of short and long nails used was variable.⁹⁻¹¹ Advantages of using a short nail for the treatment of these fractures include shorter fluoroscopy time and shorter operative time.¹²⁻¹⁴ However, there is a risk of fracture distal to these implants in patients with osteoporosis.³ The advantage of a long cephalomedullary nail is protection of the entire femur in pathologic osteoporotic bone.¹⁵

Given the paucity of literature on the InterTAN cephalomedullary nail, the goal of this study was to compare perioperative measures and postoperative orthopedic complications between patients who

underwent placement of short and long InterTAN nails for the treatment of unstable pertrochanteric fractures. The authors hypothesized that short nails would have increased periprosthetic fractures but shorter surgical and fluoroscopy time and less blood loss compared with long nails.

MATERIALS AND METHODS

A retrospective study was conducted according to the approved institutional review board protocol. Patients were reviewed from January 2005 through November 2010 and were included in the study if they had an AO/OTA 31-A2 or AO/OTA 31-A3 pertrochanteric fracture treated with a cephalomedullary nail (short or long InterTAN).¹⁶ All included patients had at least 8 weeks of follow-up. Patients were excluded if they had extension of the fracture into the subtrochanteric region. All patients underwent surgery at an urban Level I trauma center or a suburban community hospital.

At the study sites, patients with AO/OTA 31-A1 pertrochanteric fractures undergo internal fixation with a sliding hip screw device and patients with AO/OTA 31-A2 and A3 pertrochanteric fractures undergo internal fixation with an InterTAN cephalomedullary nail.¹⁶ The definition of stability and the choice of fixation device were subject to the discretion of the treating surgeon. The InterTAN nail is available in short and long versions. Before 2008, the study sites primarily used short cephalomedullary nails for the treatment of pertrochanteric fractures, and after 2008, long nails began to be used. Of note, the long InterTAN radius of curvature decreased from 2 m to 1.5 m during the study period, but this study did not specifically address the effect of this change on complications.

Intraoperatively, patients were placed supine on the fracture table and the fracture was reduced. Nails were inserted with a closed technique under fluoroscopic control. Postoperatively, patients in both groups began weight bearing as tolerated

with an assist device. They were seen by physical therapy on postoperative day 1 and were followed daily throughout their inpatient stay.

Information recorded included surgical time, estimated blood loss, fluoroscopy time, and postoperative orthopedic complications. Postoperative orthopedic complications included infection, screw cutout, periprosthetic femur fracture, and implant failure, defined as fracture of the nail or screw. Patients were identified as having an infection only if they required return to the operating room for irrigation and debridement or if they required removal of components.

The Mann-Whitney-Wilcoxon rank-sum test was used to compare continuous variables between treatment groups, and chi-square tests were used, with Cochran correction as appropriate, to compare categorical variables between treatment groups. $P < .05$ was considered statistically significant.

RESULTS

A total of 169 patients were identified with an AO/OTA 31-A2 or A3 pertrochanteric fracture treated with a short or long InterTAN cephalomedullary nail. All patients had a minimum follow-up of 8 weeks. Mean radiographic follow-up was 298 days.

During the study period, 72 patients (42.6%) were treated with a short cephalomedullary nail (**Figure 1A**) and 97 patients (57.4%) were treated with a long nail. Demographic features were similar between the 2 groups (**Table 1**). Surgical time was shorter ($P = .001$), estimated blood loss was less ($P = .002$), and a trend was seen toward shorter fluoroscopy time in the short nail group ($P = .071$, **Table 2**). Data on fluoroscopy time were limited by missing values ($n = 129$).

No differences were detected between groups in the rate of infection (short nail group, 1 of 72, 1.4%; long nail group, 3 of 97, 3.1%; $P = .637$) or the rate of implant failure (short nail group, 1 of 72, 1.4%;

long nail group, 1 of 97, 1.0%; $P=.881$) (Table 3). In the long nail group, 5 failures occurred by screw cutout (5.2%), but none occurred in the short nail group ($P=.134$). Mean tip-apex distance was longer in the short nail group (23.2 mm) than in the long nail group (20.0 mm) ($P=.020$). After controlling for tip-apex distance, implant type was not an independent predictor of screw cutout ($P=.997$). Mean time to recognition of screw cutout for the long nail group was 29.4 days (range, 12-57 days). There were 6 periprosthetic femur fractures (8.3%) (Figure 1B) in the short nail group and none in the long nail group ($P=.013$). Mean time to recognition of periprosthetic femur fracture in the short nail group was 171.3 days (range, 1-563 days).

DISCUSSION

This study compared short and long InterTAN cephalomedullary nails for the treatment of AO/OTA 31-A2 and A3 peritrochanteric fractures. The results showed that although overall implant failure and screw cutout were not different in the 2 groups, the use of short nails for peritrochanteric femur fractures is associated with increased periprosthetic fracture compared with long nails. However, short nails are associated with shorter operative time and less estimated blood loss.

Screw cutout is an important complication after treatment of peritrochanteric fractures,¹⁷ and the current study showed a trend toward increased screw cutout in long nails (long nail group, 5 of 97, 5.2%; short nail group, 0 of 72, 0%; $P=.134$). The trend toward more screw cutout in the long nail group may relate to lag screw position. Of the 5 patients in the long nail group with screw cutout, 3 had a tip-apex distance greater than 25 mm, which has been shown to be a predictor of screw cutout for cephalomedullary nails.¹⁸ Overall, the long cephalomedullary nail group had shorter mean tip-apex distance than the short nail group (20.0 vs 23.2 mm, $P=.020$). After controlling for

Table 1

Demographics			
Variable	Short Nail (n=72)	Long Nail (n=97)	P
Age, mean±SD, y	76.2±12.3	76.3±15.2	.621
Female sex, No.	54 (75.0%)	67 (55.4%)	.501

Table 2

Perioperative Measures			
Variable	Mean±SD		P
	Short Nail (n=72)	Long Nail (n=97)	
Surgery time, min	63.8±20.0	82.6±26.4	.001
Estimated blood loss, mL	161.4±122.4	208.1±116.9	.002
Fluoroscopy time, s	90.0±23.7	141.6±61.0	.071

Table 3

Orthopedic Complications			
Outcome	No.		P
	Short Nail (n=72)	Long Nail (n=97)	
Infection	1 (1.4%)	3 (3.1%)	.637
Screw cutout	0 (0%)	5 (5.2%)	.134
Femur fracture	6 (8.3%)	0 (0%)	.013
Implant failure	1 (1.4%)	1 (1.0%)	.881

tip-apex distance, implant type was not an independent risk factor for screw cutout ($P=.997$). Screw cutout occurred within 57 days of surgery, suggesting the need for increased awareness of this complication in the early postoperative period.

In the largest series that compared short and long cephalomedullary nails, Kleweno et al¹⁹ retrospectively studied 219 patients treated with a short nail and 340 patients treated with a long nail for AO/OTA 31-A1, A2, and A3 fractures. They used short and long Gamma 2 and 3 nails (Stryker) as well as short and long Trochanteric Fixation Nails (Synthes, Paoli, Pennsylvania) and found that the rate of screw cutout was not different between the 2 groups (short nail group, 5 of

219, 2%; long nail group, 11 of 340, 3%; $P=.51$). In 2 smaller retrospective studies of patients with AO/OTA 31-A1 and A2 peritrochanteric fractures treated with a Gamma 3 nail or Trochanteric Fixation Nail, no difference in screw cutout was noted between short and long nails.^{14,20} The trend in screw cutout also may be explained by variations in lag screw design among the nails used in these studies. In addition to the lag screw, the InterTAN nail uses a compression screw with a 7.8-mm diameter. Combined with the 11-mm diameter of the lag screw, the total integrated lag-compression screw diameter is 15.25 mm. In contrast, the Gamma nail lag screw has a 10.5-mm diameter and the Trochanteric Fixation Nail uses ei-

ther an 11-mm-diameter lag screw or a helical blade. The use of the compression screw and the larger overall diameter of the lag-compression screw construct may alter the biomechanical properties of the nail. Increased screw cutout associated with long nails also may relate to transfer of force from the distal aspect of the nail to the proximal aspect. The shorter length limits the transfer of force from the distal aspect of a short nail. To the authors' knowledge, these concepts have not been tested and require further evaluation.

The rate of periprosthetic fracture was decreased in the long nail group (short nail group, 6 of 72, 8.3%; long nail group, 0 of 97, 0%; $P=.013$). The large range in the timing of periprosthetic femur fractures (range, 1-563 days) suggests that the timing of this complication is not predictable. The literature on secondary fracture around cephalomedullary nails is inconclusive. The overall rate of periprosthetic fracture for short cephalomedullary nails has been reported as 0% to 20%.²¹⁻²⁸ In a systematic review of 13,568 patients, Norris et al²⁹ showed a trend toward increased fracture in short nails compared with long nails (1.7% vs 1.1%, respectively; $P=.28$). These authors concluded that the rate of secondary fracture may be reduced with a long nail design, but further study is required. In a more recent retrospective study, Vaughn et al³⁰ found a trend toward more periprosthetic fractures with short nails used to treat AO/OTA 31-A1 and A2 fractures (short nail group, 2 of 60, 3.3%; long nail group, 0 of 196, 0%; $P=.054$). The authors concluded that their study was underpowered to detect a difference and recommended further study. Other retrospective studies that compared long and short cephalomedullary nails showed no difference in periprosthetic fractures.^{14,19,20,30} In theory, long cephalomedullary nails prevent future periprosthetic fracture by spanning the entire femur and are preferred when the fracture extends to the subtrochanteric region or when protection of the entire femoral shaft is nec-

essary, as in severe osteoporosis or known metastatic disease.¹⁵ The current results suggest that a long cephalomedullary nail offers the benefit of protecting the entire femur. However, given conflicting findings, the association between nail length and secondary fracture requires further study.

Earlier studies showed consistently longer operative time for long nails, as shown in the current study. In a randomized control trial of AO/OTA 31-A3 fractures, Okcu et al¹³ found decreased operative time for short nails compared with long nails (52.6 vs 71.8 minutes, $P<.001$). These findings are consistent with other retrospective studies comparing long nails with short nails.^{14,19,20,30,31} Shorter operative time improves both patient safety and operating room efficiency. For patients with multiple comorbidities, shorter operative time decreases postoperative complications.^{32,33} Further, decreased time on the fracture table is associated with decreased risk of pudendal nerve palsy.³⁴ Finally, shorter operative times promote improved operating room efficiency regarding operating room turnover and cost.³⁵

The increased operative time associated with long nails in the current study is likely related to the placement of distal interlocking screws. In the current study, these were placed freehand with perfect circle technique. In contrast, the short nail has a jig that allows placement of the distal interlocking screws without the use of fluoroscopy. Kleweno et al¹⁹ showed the effect of distal interlocking screw placement on surgical time for long nails. They reported that long nails placed with no distal interlocking screws had a similar operative time to that for short nails (long nails, 59 minutes; short nails, 51 minutes). Although the difference was statistically significant ($P=.001$), 8 minutes is substantially shorter than the difference in surgical time for the long nail group as a whole (with and without distal interlocks) and the surgical time for short nails (70 vs 51 minutes, respectively; $P<.001$), and

this suggests that placement of the distal interlocks was primarily responsible for the longer surgical time in the long nail group. Distal interlocking in the current study was also likely responsible for the trend toward increased fluoroscopy time associated with long nails compared with short nails (141.6 vs 90.0 seconds, respectively; $P=.071$). These findings are consistent with a prospective study by Okcu et al¹³ that showed fluoroscopy time of 58.6 seconds for short nails and 75.3 seconds for long nails. Radiation associated with intraoperative fluoroscopy is an important consideration for the safety of surgical staff. Significant radiation dosage is associated with exposure to intraoperative fluoroscopy for the patient and over the course of a career in orthopedic surgery.³⁶ Even low doses of ionizing radiation are associated with cancer, 50 mSv for acute exposure and 100 mSv for chronic exposure, and exposure should be minimized where possible.³⁷ The use of short nails offers an avenue for reducing radiation exposure.

The current study also showed reduced estimated blood loss for short nails compared with long nails (161.4 mL vs 208.1 mL, respectively; $P=.002$). These findings are consistent with previous retrospective studies.^{14,20} Increased blood loss with long nails is likely a result of the reaming process. Long nails require reaming of the entire femoral shaft, whereas short nails do not. Nevertheless, reduced estimated blood loss associated with short nails may not necessarily translate to decreased transfusion requirements, with conflicting evidence from earlier studies. In a retrospective study, Boone et al¹⁴ showed increased transfusion requirements for long nails compared with short nails (57.1% vs 40.2%, respectively; $P=.022$). In contrast, Hou et al²⁰ showed only a trend toward more transfusions with long nails compared with short nails (45.4% vs 42.0%, respectively; $P=.462$). Transfusion was not a primary end point for these studies, and the study by Hou et al²⁰ may

have been underpowered to detect a difference. Further, these studies did not offer information on transfusion thresholds. Although the current study did not specifically consider complications associated with blood loss, decreased blood loss is associated with decreased postoperative medical complications. Reduced blood loss is a particular advantage in elderly patients and patients with multiple comorbidities, and it is associated with decreased complications.³⁸ Because of the shorter operative time and reduced blood loss associated with short nails compared with long nails, the study sites prefer the use of short nails for patients with significant medical comorbidities, such as severe aortic stenosis.

Limitations

The current study is limited by its retrospective design and the associated biases. In addition, the minimum follow-up was 8 weeks. This patient cohort is difficult to follow in many settings, and the minimum follow-up in this study was comparable to that in other studies.^{17,18,39} This study highlights important differences between short and long InterTAN nails, and this device has been studied less extensively than other implants. Given the retrospective design of most published studies, the small sample size of earlier prospective studies, and the relative paucity of data on functional status, further study of the benefit of short and long nails is required, and at least 1 randomized prospective study comparing short and long nails (NCT02285127) is under way.

CONCLUSION

This study found a similar overall rate of orthopedic complications with short and long cephalomedullary nails for the treatment of AO/OTA 31-A2 and A3 pertrochanteric fracture. These results confirm the suspected advantages of short cephalomedullary nails, including reduced surgical time and less blood loss. More femoral shaft fractures were ob-

served with short nails. After controlling for tip-apex distance, implant type was not an independent risk factor for screw cutout.

REFERENCES

1. Brauer CA, Coca-Perraillon M, Cutler DM, Rosen AB. Incidence and mortality of hip fractures in the United States. *JAMA*. 2009; 302(14):1573-1579.
2. Kubiak EN, Bong M, Park SS, Kummer F, Egol K, Koval KJ. Intramedullary fixation of unstable intertrochanteric hip fractures: one or two lag screws. *J Orthop Trauma*. 2004; 18(1):12-17.
3. Rosenblum SF, Zuckerman JD, Kummer FJ, Tam BS. A biomechanical evaluation of the Gamma nail. *J Bone Joint Surg Br*. 1992; 74(3):352-357.
4. Queally JM, Harris E, Handoll HH, Parker MJ. Intramedullary nails for extracapsular hip fractures in adults. *Cochrane Database Syst Rev*. 2014; 9:CD004961.
5. Adams CI, Robinson CM, Court-Brown CM, McQueen MM. Prospective randomized controlled trial of an intramedullary nail versus dynamic screw and plate for intertrochanteric fractures of the femur. *J Orthop Trauma*. 2001; 15(6):394-400.
6. Utrilla AL, Reig JS, Muñoz FM, Tufanisco CB. Trochanteric gamma nail and compression hip screw for trochanteric fractures: a randomized, prospective, comparative study in 210 elderly patients with a new design of the gamma nail. *J Orthop Trauma*. 2005; 19(4):229-233.
7. Crawford CH, Malkani AL, Cordray S, Roberts CS, Sligar W. The trochanteric nail versus the sliding hip screw for intertrochanteric hip fractures: a review of 93 cases. *J Trauma*. 2006; 60(2):325-328.
8. Ruecker AH, Rupprecht M, Gruber M, et al. The treatment of intertrochanteric fractures: results using an intramedullary nail with integrated cephalocervical screws and linear compression. *J Orthop Trauma*. 2009; 23(1):22-30.
9. Matre K, Vinje T, Havelin LI, et al. TRIGEN INTERTAN intramedullary nail versus sliding hip screw: a prospective, randomized multicenter study on pain, function, and complications in 684 patients with an intertrochanteric or subtrochanteric fracture and one year of follow-up. *J Bone Joint Surg Am*. 2013; 95(3):200-208.
10. Zhang S, Zhang K, Jia Y, Yu B, Feng W. InterTan nail versus Proximal Femoral Nail Antirotaion-Asia in the treatment of unstable trochanteric fractures. *Orthopedics*. 2013; 36(3):e288-e294.
11. Erez O, Dougherty PJ. Early complications associated with cephalomedullary nail for intertrochanteric hip fractures. *J Trauma Acute Care Surg*. 2012; 72(2):E101-E105.
12. Kreder HJ. Principles and evidence: the optimal treatment of pertrochanteric hip fractures. Commentary on an article by Kjell Matre, MD, et al.: "TRIGEN INTERTAN intramedullary nail versus sliding hip screw: a prospective, randomized multicenter study on pain, function, and complications in 684 patients with an intertrochanteric or subtrochanteric fracture and one year of follow-up". *J Bone Joint Surg Am*. 2013; 95(3):e16.
13. Okcu G, Ozkayin N, Okta C, Topcu I, Aktuglu K. Which implant is better for treating reverse obliquity fractures of the proximal femur: a standard or long nail? *Clin Orthop Relat Res*. 2013; 471(9):2768-2775.
14. Boone C, Carlberg KN, Koueiter DM, et al. Short versus long intramedullary nails for treatment of intertrochanteric femur fractures (OTA 31-A1 and A2). *J Orthop Trauma*. 2014; 28(5):e96-e100.
15. Kanakaris NK, Tosounidis TH, Giannoudis PV. Nailing intertrochanteric hip fractures: short versus long; locked versus nonlocked. *J Orthop Trauma*. 2015; 29(suppl 4):S10-S16.
16. Marsh JL, Slongo TF, Agel J, et al. Fracture and dislocation classification compendium—2007: Orthopaedic Trauma Association classification, database and outcomes committee. *J Orthop Trauma*. 2007; 21(10)(suppl):S1-S133.
17. Baumgaertner MR, Curtin SL, Lindskog DM, Keggi JM. The value of the tip-apex distance in predicting failure of fixation of pertrochanteric fractures of the hip. *J Bone Joint Surg Am*. 1995; 77(7):1058-1064.
18. De Bruijn K, den Hartog D, Tuinebreijer W, Roukema G. Reliability of predictors for screw cutout in intertrochanteric hip fractures. *J Bone Joint Surg Am*. 2012; 94(14):1266-1272.
19. Kleweno C, Morgan J, Redshaw J, et al. Short versus long cephalomedullary nails for the treatment of intertrochanteric hip fractures in patients older than 65 years. *J Orthop Trauma*. 2014; 28(7):391-397.
20. Hou Z, Bowen TR, Irgit KS, et al. Treatment of pertrochanteric fractures (OTA 31-A1 and A2): long versus short cephalomedullary nailing. *J Orthop Trauma*. 2013; 27(6):318-324.
21. Lindsey RW, Teal P, Probe RA, Rhoads D, Davenport S, Schauder K. Early experience with the gamma interlocking nail for pertrochanteric fractures of the proximal femur. *J Trauma*. 1991; 31(12):1649-1658.
22. Hesse B, Gächter A. Complications following the treatment of trochanteric fractures with the gamma nail. *Arch Orthop Trauma Surg*. 2004; 124(10):692-698.
23. Bridle SH, Patel AD, Bircher M, Calvert PT. Fixation of intertrochanteric fractures of the femur: a randomised prospective comparison

- of the gamma nail and the dynamic hip screw. *J Bone Joint Surg Br*. 1991; 73(2):330-334.
24. Bhandari M, Schemitsch E, Jönsson A, Zlowodzki M, Haidukewych GJ. Gamma nails revisited. Gamma nails versus compression hip screws in the management of intertrochanteric fractures of the hip: a meta-analysis. *J Orthop Trauma*. 2009; 23(6):460-464.
 25. Madsen JE, Naess L, Aune AK, Alho A, Eke-land A, Strømsøe K. Dynamic hip screw with trochanteric stabilizing plate in the treatment of unstable proximal femoral fractures: a comparative study with the Gamma nail and compression hip screw. *J Orthop Trauma*. 1998; 12(4):241-248.
 26. Butt MS, Krikler SJ, Nafie S, Ali MS. Comparison of dynamic hip screw and gamma nail: a prospective, randomized, controlled trial. *Injury*. 1995; 26(9):615-618.
 27. Ahrengart L, Törnkvist H, Fornander P, et al. A randomized study of the compression hip screw and Gamma nail in 426 fractures. *Clin Orthop Relat Res*. 2002; 401:209-222.
 28. Schipper IB, Steyerberg EW, Castelein RM, et al. Treatment of unstable trochanteric fractures: randomised comparison of the gamma nail and the proximal femoral nail. *J Bone Joint Surg Br*. 2004; 86(1):86-94.
 29. Norris R, Bhattacharjee D, Parker MJ. Occurrence of secondary fracture around intramedullary nails used for trochanteric hip fractures: a systematic review of 13,568 patients. *Injury*. 2012; 43(6):706-711.
 30. Vaughn J, Cohen E, Vopat BG, Kane P, Abbood E, Born C. Complications of short versus long cephalomedullary nail for intertrochanteric femur fractures, minimum 1 year follow-up. *Eur J Orthop Surg Traumatol*. 2015; 25(4):665-670.
 31. Li Z, Liu Y, Liang Y, Zhao C, Zhang Y. Short versus long intramedullary nails for the treatment of intertrochanteric hip fractures in patients older than 65 years. *Int J Clin Exp Med*. 2015; 8(4):6299-6302.
 32. Belmont PJ Jr, Goodman GP, Waterman BR, Bader JO, Schoenfeld AJ. Thirty-day postoperative complications and mortality following total knee arthroplasty: incidence and risk factors among a national sample of 15,321 patients. *J Bone Joint Surg Am*. 2014; 96(1):20-26.
 33. Schoenfeld AJ, Carey PA, Cleveland AW III, Bader JO, Bono CM. Patient factors, comorbidities, and surgical characteristics that increase mortality and complication risk after spinal arthrodesis: a prognostic study based on 5,887 patients. *Spine J*. 2013; 13(10):1171-1179.
 34. Brumback RJ, Ellison TS, Molligan H, Molligan DJ, Mahaffey S, Schmidhauser C. Pudendal nerve palsy complicating intramedullary nailing of the femur. *J Bone Joint Surg Am*. 1992; 74(10):1450-1455.
 35. Girotto JA, Koltz PF, Drugas G. Optimizing your operating room: or, why large, traditional hospitals don't work. *Int J Surg*. 2010; 8(5):359-367.
 36. Baumgartner R, Libuit K, Ren D, et al. Reduction of radiation exposure from C-arm fluoroscopy during orthopaedic trauma operations with introduction of real-time dosimetry. *J Orthop Trauma*. 2016; 30(2):e53-e58.
 37. Brenner DJ, Doll R, Goodhead DT, et al. Cancer risks attributable to low doses of ionizing radiation: assessing what we really know. *Proc Natl Acad Sci U S A*. 2003; 100(24):13761-13766.
 38. Foss NB, Kehlet H. Hidden blood loss after surgery for hip fracture. *J Bone Joint Surg Br*. 2006; 88(8):1053-1059.
 39. Flores SA, Woolridge A, Caroom C, Jenkins M. The utility of the tip-apex distance in predicting axial migration and cutout with the trochanteric fixation nail system helical blade. *J Orthop Trauma*. 2016; 30(6):e207-e211.